



# Newsletter 2024

[www.tanner-eyes.co.uk](http://www.tanner-eyes.co.uk)

0800 644 0700  
0800 644 0900



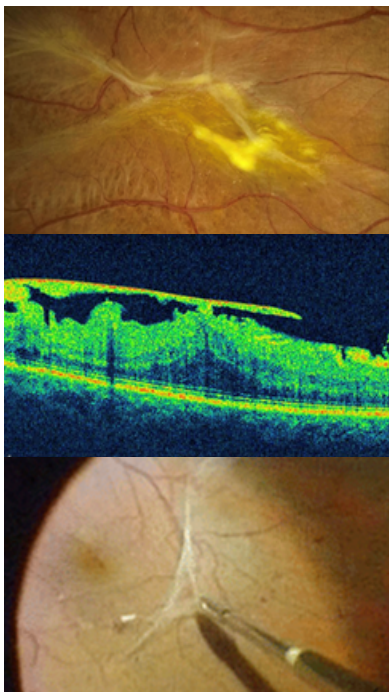
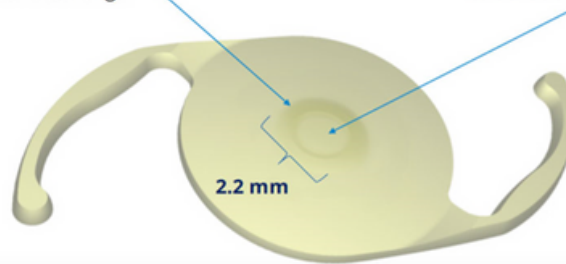
## REFRACTIVE CATARACT SURGERY

Recent advances include improved stability and accuracy of refractive outcome using toric implants together with the next generation biometry formula (Barrett and Kane). This means I am now able to correct astigmatism down to half a dioptre. This is particularly important in patients wishing to have extended depth of focus implants. I now routinely offer the Alcon Vivity extended depth of focus implant which has been a game changer, enabling 1 ½ dioptres of aberration free accommodation (or more with micro mono vision). The lack of side effects associated with the Vivity lens, compared to older multifocal lens models, makes it an increasingly popular option.

Alcon Vivity Lens Implant – X-WAVE™ Technology consists of 2 smooth-surface transition elements that stretch and shift the wavefront

**Surface Transition #1:**  
Slightly Elevated Smooth Plateau (~1 µm high) **stretches** the wavefront, creating a continuous extended focal range

**Surface Transition #2:**  
Small Curvature Change (across the ~2.2 mm region) **shifts** the wavefront to utilise all available light energy

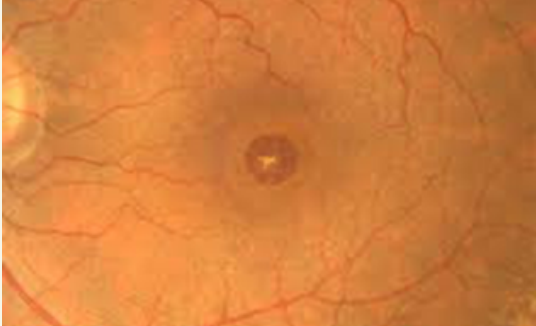

## EPIRETINAL MEMBRANE

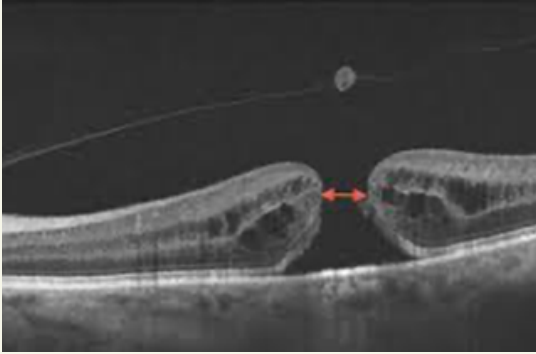
Many of you have OCT scanners in practice and of course are routinely picking up more epiretinal membranes than may have been seen historically. As a general rule if the membrane is not affecting vision, you do not need to refer these patients in but monitor them, perhaps on a six-monthly basis. If there is any evidence of advancement, then of course I would be happy to see and review. A common misconception amongst patients presenting for epiretinal membrane removal is that they will need to posture post operatively with a gas fill. This is possible but is certainly not routine. The majority of patients undergoing epiretinal membrane surgery will not require intraocular gas fill or post operative posturing. Vitrectomy offers an approx. 80-90% chance of significant visual improvement.

# MACULAR HOLES

We are routinely achieving over 95% successful closure of macular holes with one vitrectomy surgery. Increasingly, I am combining vitrectomy surgery with cataract surgery at the same procedure. This ensures a more rapid visual recovery and of course, in those over 50, early rapid onset of cataract is inevitable following vitrectomy surgery anyway. Face down posturing after macular hole repair is now considered less critical and in small macular holes I usually recommend two days face down posturing, day time only. All macular vitrectomy procedures are now carried out through the latest sutureless 25g (0.5mm) valved ports, helping ensure a rapid pain free recovery.

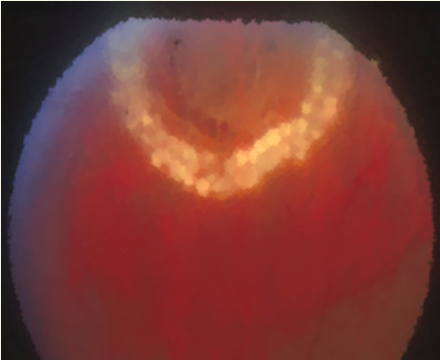


GRADE 4 FULL THICKNESS MACULAR HOLE



OCT SCAN OF GRADE 3 FULL THICKNESS MACULAR HOLE WITH OVERLYING PSEUDO-OPERCULUM

LASER REACTION AROUND ACUTE HORSESHOE RETINAL TEAR

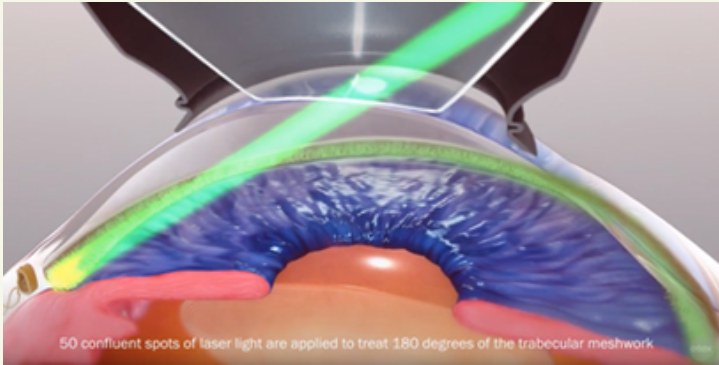


# RETINAL HOLES

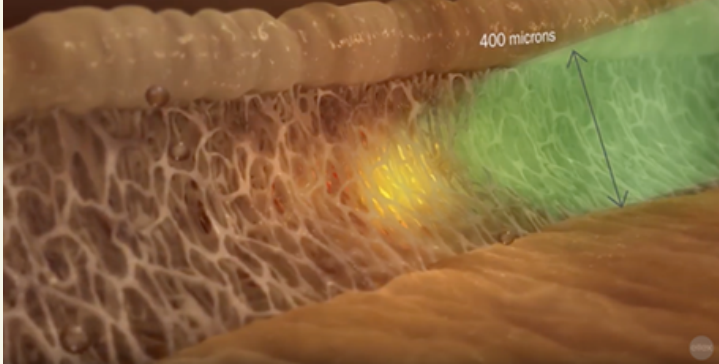
With the widespread adoption of Optomap imaging, more routine asymptomatic holes are being identified in Optomap images. The vast majority of these asymptomatic holes can be observed without referral and it is unusual for treatment to be required in asymptomatic lesions. Of course ,there are always exceptions and I would be happy to see any cases of concern.

# SELECTIVE LASER TRABECULOPLASTY (SLT)

I am increasingly offering SLT as first line treatment for glaucoma and ocular hypertension, in preference to drops with their associated compliance and side effect issues (LIGHT study and NICE guidance). Many patients who develop side effects on existing glaucoma medications are also now successfully stopping drops after SLT, with good pressure control and less ocular surface reactions.

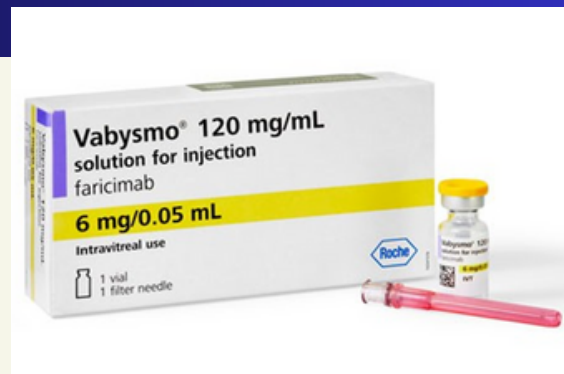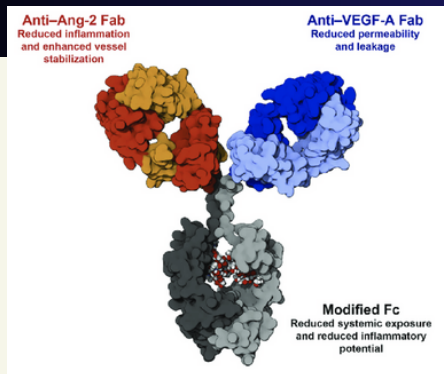


50 confluent spots of laser light are applied to treat 180 degrees of the trabecular meshwork



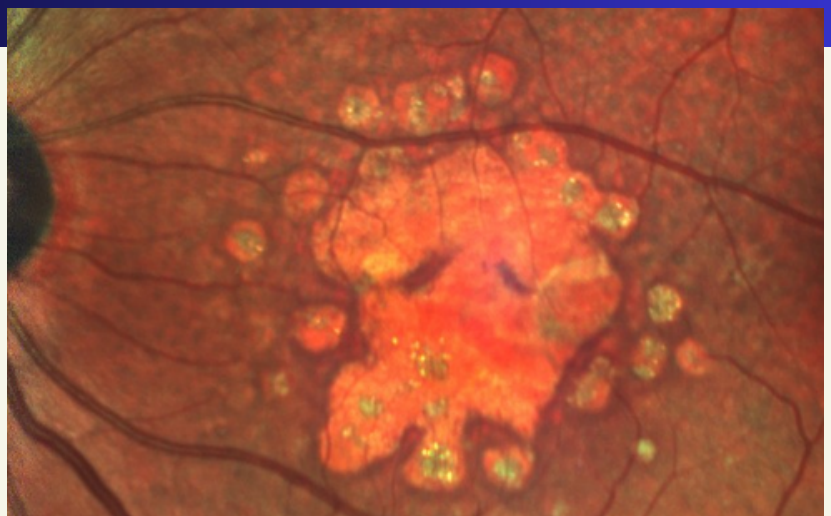
# AGE RELATED MACULAR DEGENERATION

**WET** - The introduction of Faricimab (Vabysmo) as the latest intravitreal antigrowth factor therapy for wet age related macular degeneration has allowed many of my patients to extend their treatment interval towards a four month regime. Increased efficacy results from the targeting of both VEGF A and ANG 2 unlike previous single target drugs. This is obviously a tremendous saving on the burden of hospital visits and Faricimab is now my first line treatment for wet age related macular disease in the majority of cases.



THE FARICIMAB (VABYSMO) ANTIBODY STRUCTURE

**DRY** - An exciting new development in the near future will be the introduction of anticomplement injections to treat dry age related macular degeneration. Pegcetacoplan is already licensed in the USA for those with documented progressive geographic atrophy (OAKS and DERBY trials). Approval is awaited in the UK for what is the first convincing treatment shown to decrease photoreceptor loss in dry age related macular disease. The challenge will of course be identifying suitable patients and ensuring sufficient capacity to treat what is likely to be a significant workload.



# Tanner - Eyes

## A Centre of Excellence in Cataract and Retinal Surgery

Cataract Surgery

Yag laser Capsulotomy

Age Related Macular  
Degeneration

Epiretinal Membrane

Glaucoma

Macular Hole

Vitreous Floaters

Blepharitis and  
Dry Eye



**0800 644 0700 • 0800 644 0900**

[secretary@tanner-eyes.co.uk](mailto:secretary@tanner-eyes.co.uk) • [www.tanner-eyes.co.uk](http://www.tanner-eyes.co.uk)

Circle Hospital, Reading

Dunedin Hospital, Reading

Princess Margaret Hospital, Windsor