

Mr Vaughan Tanner
BSc MBBS FRCOphth
Consultant Ophthalmic Surgeon

Telephone: 0800 644 0900
0800 644 0700

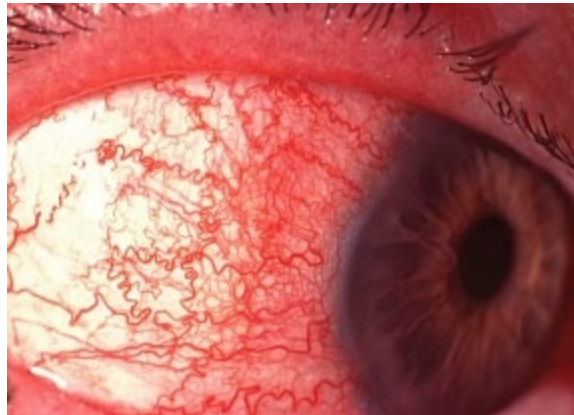
<http://www.tanner-eyes.co.uk>

Patient Information:

Iritis (anterior uveitis)

This is an inflammatory condition affecting the iris, (the coloured part of your eye). It can be associated with other inflammatory conditions of the body, for example arthritis, but in most cases the cause remains unknown.

It is a common condition which tends to recur, and usually only affects one eye at any one time.



**Photograph of a severe case of iritis.
The red, engorged blood vessels are mainly
around the cornea rather than all over the eye**

Signs and symptoms

Aching, painful red eye with small pupil, blurred vision and sensitivity to light.

Treatment

It is important that this condition is treated quickly, it can be difficult to diagnose without certain equipment, which is often not available at your local doctor's surgery.

The usual treatment is steroid drops which may be used frequently at first, then gradually tailed off. You must not suddenly stop using the drops, or the iritis may recur.

You will often be given drops to dilate your pupil. This will cause blurring of vision and difficulty in focusing, and may also increase your sensitivity to light, but it is a vital part of the treatment for iritis. If the pupil is not dilated, the inflamed iris will stick to the lens, which can lead to complications. In order to cause minimal inconvenience the dilating drops are usually used last thing at night.

Disclaimer

The information provided in this document is intended as a useful aid to general practitioners, optometrists and patients. It is impossible to diagnose and treat patients adequately without a thorough eye examination by a qualified ophthalmologist, optometrist or your general practitioner. Hopefully the information will be of use prior to and following a consultation which it supplements and does not replace.

Copyright

All images and graphics used in this document are subject to copyright law. Mr Tanner is particularly grateful to Mr JJ Kanski and for allowing reproduction of several of his clinical photos on this document.